

PATIENT
Bella Orduz

PRESENTING CLINICAL SIGNS

History: Bella referred to evaluate a heart murmur noted ~ 3 years ago. She is in need of some dental work. Eating well with normal activity. On exam: NSR, grade III/VI murmur with PMI left apical area, PSS, lung fields clear. BP: 140 mmHg. No medications. *No sedation for study

SPECIES
Canine

ECHOCARDIOGRAM FINDINGS

2D, m-mode, color flow and Doppler imaging is available.

Left ventricle: The LV diameter is normal with adequate myocardial function. LV wall thicknesses are normal.

Left atrium: The left atrium is mildly dilated.

Mitral valve: The mitral valve is diffusely thickened with no prolapse into the left atrial lumen. Mild eccentric mitral regurgitation with a normal velocity.

Aortic valve/aorta: The aortic valve is normal in morphology and mobility. Normal aortic outflow velocity; laminar flow. No aortic insufficiency.

Right ventricle: Normal right ventricular diameter and morphology indicating no overt evidence of pulmonary arterial hypertension.

Right atrium: Normal RA dimension.

Tricuspid valve: The tricuspid valve appears normal with trace tricuspid regurgitation; velocity consistent with early PAH.

Pulmonic valve/pulmonary artery: The pulmonic valve is normal in morphology and mobility. No pulmonic insufficiency. Normal RVOT velocity; laminar flow.

Pericardium/other: No pericardial or pleural effusion noted. No obvious cardiac masses.

Heart rhythm: ECG reveals a sinus rhythm with an average HR of bpm.

BREED
Boston Terrier

SEX
FS

AGE
8 years

WEIGHT
23.6 lbs

INTERPRETED BY

Maggie Machen
Lamy, DVM
DACVIM (Cardiology)

2-Dimensional Measurements

| | |
|--------------------|-----|
| Ao diam (cm) | 1.6 |
| LA diam (cm) | 2.4 |
| LA:Ao (Swe) | 1.5 |
| IVS thickness (cm) | 0.7 |
| LVID diastole (cm) | 2.8 |
| PW thickness (cm) | 0.7 |
| LVID systole (cm) | 1.3 |
| FS (%) | 54 |

Doppler Measurements

| | |
|----------------|------|
| PV Vmax (m/s) | 0.83 |
| AoV Vmax (m/s) | 1.5 |
| MR Vmax (m/s) | 6.1 |
| TR Vmax (m/s) | 3.0 |
| TR PG (mmHg) | 36 |

IMAGING PERFORMED BY

Pamela Harrigan,
RDCS

INTERPRETATION OF THE FINDINGS

The cause of the murmur is chronic degenerative valve disease causing mild mitral and trace tricuspid regurgitation. Lack of significant left atrial enlargement indicates the current risk for complication is low. Early PAH is noted, which is of unknown significance in a dog without respiratory disease. No concurrent issues are noted in this study.

HOSPITAL NAME

Mass Veterinary Services

REFERRING VET

Dr. Masloski

Assessment of progression in the future will help predict long term prognosis, which is highly variable at this stage (B1).

RECOMMENDATIONS

- In an asymptomatic dog without significant left atrial enlargement, no cardiac medications are clearly indicated.
- Omega fatty acid supplementation and mild salt restriction may be of some long-term benefit.

INVOICE
27614

DATE
11/22/22



PATIENT
Bella Orduz

SPECIES
Canine

BREED
Boston Terrier

SEX
FS

AGE
8 years

WEIGHT
23.6 lbs

INTERPRETED BY
Maggie Machen
Lamy, DVM
DACVIM (Cardiology)

IMAGING PERFORMED BY
Pamela Harrigan,
RDCS

HOSPITAL NAME
Mass Veterinary
Services

REFERRING VET
Dr. Masloski

INVOICE
27614

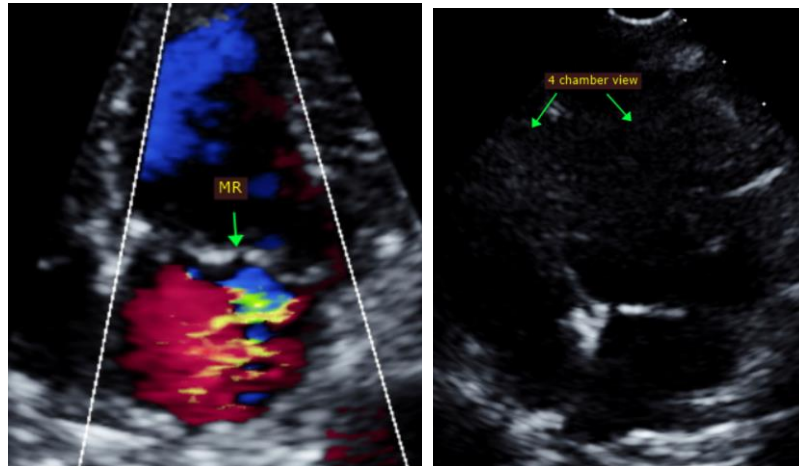
DATE
11/22/22

- Anesthetic risk is considered mild if needed. Cardiac protective drug choices (opioid/benzodiazepine premedication, propofol or alfaxalone induction, isoflurane gas) are recommended. Pre-oxygenate for 5-10 minutes prior to induction. Monitor for arrhythmias, hypotension, and hypoxia both intra and post-operatively and intervene as necessary. Mild IV fluid restriction is recommended to avoid fluid overload. Avoid heart rate stimulating drugs such as atropine unless clinically indicated.
- Monitor for development of a cough, labored breathing, exercise intolerance or collapse episodes.

PLAN

- Recommend conservative monitoring with a recheck echocardiogram in 6 months, sooner if any development of clinical signs.

IMAGES



The information and recommendations provided are based on the images presented by the referring veterinarian. No evaluation can be communicated regarding pathology that was not visible in the image/video clips provided.

Thank you for this referral. This report was generated using transcription software, and minor dictation errors may be present. If the clinical or image interpretation does not parallel your findings or if I can be of any further assistance please contact me.

Maggie Machen Lamy, DVM
Diplomate of the American College of Veterinary Internal Medicine (Cardiology)
info@sonopath.com

Echocardiogram performed by:

Pamela Harrigan, RDCS
Pet Animal Ultrasound Service (4paus.com)